

ORIGINAL PAPER

Clinical and Functional Outcomes of Open Reduction and Internal Fixation in Fresh Displaced Pilon Fractures

Sonowal Kiran¹, Das Chinmoy², Bhattacharyya PK³

Received on May 20, 2017; editorial approval June 20, 2017

ABSTRACT

Introduction: There are several methods for treatment of pilon fracture. We propose to evaluate the clinical and functional outcome in terms of union of the fracture, mobilisation, weight bearing, infections and wound coverage after open reduction and internal fixation in closed fresh displaced pilon fracture with the help of distal tibial locking compression plate. Even though we have conducted this study to compare our results with the various national and International studies. **Method:** We have conducted a prospective study for 40 cases of Fresh displaced tibial pilon fractures in patients aged between 18yrs - 65yrs attending the OPD and Emergency department of Orthopaedics, Gauhati Medical College & Hospital, Guwahati who met the inclusion criteria outlined below. Patients were treated by open reduction and internal fixation of the fractures with Distal Tibial lock plate with or without Fibula plating. **Results:** Patient were followed up for two years evaluated by AOFAS score and compared with standard study. From our study we have obtained 21(52.5%) of patients have Excellent result, 10(25%) of patients have Good, 7(17.5%) patients have Fair and 2(5%) have poor result. **Conclusion:** Restoration of length, articular reduction, articular congruity, axial and rotational alignment with better soft tissue handling are key to excellent functional results following fractures of tibial pilon. Final outcome depends upon chondral damage, residual articular displacement, soft tissue scarring and early mobilization. The functional result is directly proportionate to the anatomical reduction and fixation during operation and inversely proportionate to the fracture comminution.

Keywords: Articular surface, AOFAS, articular congruity, Distal tibial lock plate

INTRODUCTION

Pilon fractures often present a challenge to the orthopaedic surgeon. 'Destot' first used the term pilon fracture in 1911. The

tibial pilon comprises anatomically the distal end of the tibia including the articular surface. The three- dimensional configuration of this region appears to be designed to increase the area of the articular surface, reducing the stress on the ankle joint. By convention, all fractures of the tibia involving the distal articular surface should be classified as tibial pilon1 fractures, except for medial or lateral malleolar fractures and trimalleolar fractures where the posterior malleolar fracture involves less than 1/3 of the articular surface. Tibial pilon fractures represent <1% of lower extremity fractures and 5-7% of all tibial fractures. The treatment of this type of fracture is of current research interest, since there is no universally agreed treatment method. The choice of treatment must take into account not only the stabilization of the fracture, but also the management of the soft tissue injury which is a frequent cause of subsequent complications². Great attention must be given to the accurate reconstruction of the articular surface to avoid the development of arthritis of the ankle joint. The greatest challenge to the orthopaedic surgeon lies in the relatively tight soft tissue around the ankle. Successful treatment of displaced pilon fractures requires a thorough understanding of the injury, proper timing of treatment, and use of the proper implant placed in the correct location. Open reduction and internal fixation with distal tibial locking compression plate for pilon fracture with or without fibula fracture fixation may show excellent outcome. The purpose of this study

Address for correspondence:

¹Registrar of orthopaedics, Tezpur Medical College and Hospital, Tezpur

²Associate Professor of Orthopaedics

(Corresponding Author)

Tezpur Medical College and Hospital, Tezpur

Email: drchinmoydas@yahoo.com

Mobile: +919435043908

³ Professor of Orthopaedics, Gauhati Medical College and Hospital, Guwahati

is to throw light to the ongoing controversies about the choice of treatment modality, choice of implant and surgical approaches with the aim of increasing the functional outcome reducing the danger of skin complication like infection, sloughing and necrosis and ultimately giving the patient with least morbidity post operatively.

MATERIAL AND METHOD

We conducted a prospective study for 40 cases of Fresh displaced tibial pilon fractures in patients aged between 18yrs-65yrs attending the OPD and Emergency department of Orthopaedics, Gauhati Medical College & Hospital, Guwahati who met the inclusion criteria outlined below.

Inclusion criteria: Those patient who were admitted from from 1st April 2014 to 31st March 2015 are included and who gave written and informed consent. All displaced tibial-Pilon fractures in patients aged 18-65yrs, Closed fracture and Gustilo- Anderson type I compound pilon fracture with closed fibula fracture with Duration of injury < 2 weeks and Ipsilateral hip, knee, and contralateral lower limb functionally good enough, so as not to exert a serious adverse effect on the rehabilitation process. Patients who met the medical standards for routine elective surgery.

Exclusion criteria: Patients who do not give consent were excluded. Patients age <18 years and >65 years, Inability to take part in post operative rehabilitation, All compound fractures except Gustilo-Anderson Type 1 fractures, Medical contraindications to surgery, Duration of injury > 2 weeks, Associated ipsilateral or contralateral major limb injury affecting treatment or rehabilitation protocol, Doubtful neurovascular status of the limb. Patients with multiple major bone fractures were also excluded.

Choice of implants and Approaches: AO LCP medial distal tibial plate were selected in 43B and 43C fractures with medial comminution. In these cases we used Antero-medial approach for better visualization of fracture. AO LCP lateral distal tibial plate were selected in 43B and 43C with anterior and anterolateral comminution. In these cases we used Anterolateral approach. Associated fibular plating were done in cases where - Fibula fracture is above the ankle joint line, associated with syndesmotic.

OBSERVATION AND RESULT

Our study was conducted from 1st April 2014 to 31st March 2015. We came across 40 cases of pilon fractures. All the patients were followed up for a minimum period of six months and maximum period for 18 months. Follow up was carried out at 4, 6, 12, 16, 20 weeks and then at 6 monthly intervals. Full assessment was done at the end of 4 months from the date operation in all cases.

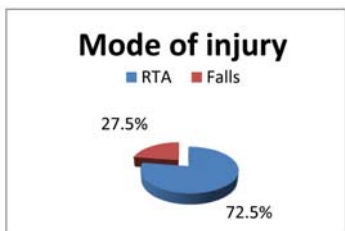


Figure 1 Mode of Injury

Table 1 Mode of injury

Study (Years)	RTA	Fall	Others
Roshdy et al ³ ,2003	66.67%	16.67%	11.11%
Singh et al ⁴ ,2011	72%	28%	0
Shabbir et al ⁵ ,2011	72.6%	38.36%	2.74%
Present study,2015	72.5%	27.5%	0

AO classification of fractures: The most common pattern of fracture was AO 43B2 (32.5%)

Table 2 AO classification of fractures

Fracture pattern	No. of patients	Percentage	Tang et al ⁶ 2012
43B1	5	12.5%	16.82%
43B2	13	32.5%	8.41%
43B3	5	12.5%	19.63%
43C1	9	22.5%	4.68%
43C2	6	15%	14.01%
43C3	2	5%	39.25%
Total	40	100	100

AOFAS score result: The functional result at union, as assessed by the AOFAS scoring system showed that the average in our series is 83.37 (min 58 and max. 90). which was comparable to other studies.

Table 3 Mean AOFAS Score

STUDY	MEAN AOFAS SCORE AT UNION
Borens et al ⁷ in 2009	86.1
Tang et al ⁶ in 2012	87.1
Chen et al ⁸ in 2014	87.8
Present study,2015	83.37

Commencement of partial weight bearing: In our study we have allowed to bear partial weight at an average of 6.8 weeks, min. 6 wks and max. 12 weeks. Full weight bearing was allowed at 16-20 weeks.

Table 4 Average time for partial weight bearing

STUDY (YEAR)	AVERAGE TIME FOR PARTIAL WEIGHT BEARING (IN WEEKS)
Ruedi et a ¹⁰ in 1979	8-10
Chen at el ¹¹ in 2014,	6-8
Present study, 2015	6-12

Union: Overall average union time is 17.16 weeks (16-20 weeks).

Range of motion of ankle: We have evaluated the patient for ankle range motion at union. We observed 8(20%) patient presented with > 30°, 27(67.5%) patients shows 15°-29° and 5 (12.5%) patients shows <15°.

Clinical results: Functional results are evaluated according to American Orthopaedics foot and ankle society score. Majority (n=21, 52.5%) of the patients in the study had excellent functional results.

Table 5 Functional results

Functional results	Excellent	Good	Satisfactory (Ex+Good)	Fair	Poor
Zeng et al ¹² in 2011	28%	50%	78%	17.5%	3.75%
Tang et al ⁶ in 2012	53%	33%	86%	8.3	4.6%
Our study, 2015	52.5%	25%	77.5%	17.5%	5%

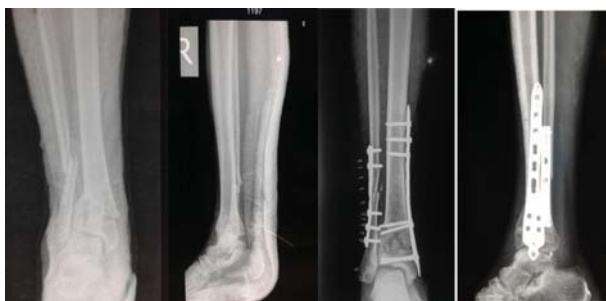

Figure 2 pre and post operative radiograph

Complication: In our study we came across our fair share of complications. There are 2 (5%) cases of superficial infection and 1 (2.5%) deep infection. There are 2 (5%) cases which went for delayed union. 1 (2.5%) case of non-union where there is no signs of union seen till 9 months of surgery. There were 2 (5%) cases of malunion with 10° varus angulation. No case of ankle instability was present in our study. There were only 5 (12.5%) patients who had restriction below 15° ROM.

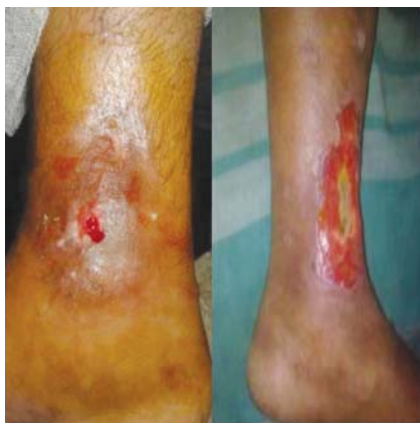

Figure 3 cases of superficial and deep infection

DISCUSSION

Fracture of the distal tibial pilon accounts for only <1% of lower extremity fractures. Commonly associated with complication as there is no universally agreed treatment protocol. The status of soft tissue, degree of comminution, articular incongruity affect long term clinical results. The challenge of achieving satisfactory results by operative procedure has resulted in various modalities of treatment. The goal is to obtain anatomical realignment of joint surface while providing enough stability for early motion. The current opinion favours the adoption of primary open reduction and internal fixation, mainly to reduce such complication and a favorable outcome. However, controversy still remains regarding several aspects of treatment options in pilon fracture. In the present study, road traffic accidents were the commonest mode of trauma. Overall out of 40 cases, in 29 (72.5%) cases the injury was due to road traffic accidents and the rest of fractures occurred due to falls; this was comparable to other studies. This was probably due to the improvement of road condition and high velocity powerful two wheelers available in the market. We allowed partial weight bearing when we saw some evidence of early callus formation. Most of the patients (28/40) were allowed partial weight bearing at 6 weeks following surgery. Other patients were allowed partial weight bearing 6-12 weeks following surgery. This is comparable to other studies. We have allowed complete weight bearing at 16-18 weeks following surgery. Ruedi et al¹¹, had allowed the partial weight bearing at 8-10 weeks although touch-down, corresponding to about 10-15 kg was permitted earlier. Full weight bearing was started between 14-20 weeks post operatively Chen et al¹² had begun partial weight bearing at 6-8 weeks. Full weight bearing was allowed at 3 months when advanced signs of union were seen on radiograph. We have observed that the result of surgical outcome is inversely proportionate to the comminution of fracture fragments. The result of both the cases of 43C3 is found to be poor. In our series, satisfactory results (Excellent + Good) were found in 77.5%, whether 17.5% were fair and 5% were poor results. This was almost comparable to other studies.

CONCLUSION

Restoration of length, articular reduction, articular congruity, axial and rotational alignment with better soft tissue handling are key to excellent functional results following fractures of tibial pilon. Final outcome depends upon chondral damage, residual articular displacement, soft tissue scarring and early mobilization. The functional result is directly proportionate to the anatomical reduction and fixation during operation and inversely proportionate to the fracture comminution. The principles and procedure of primary open reduction and internal fixation of pilon fracture with distal tibial locking compression plate with or without fibula plating contribute towards optimal reduction and good stabilization in pilon fracture. Complications such as stiffness, can be minimized with early mobilization after relieve of pain post operatively and early physiotherapy. Stiffness is found to be less where wound heals with minimal scar. Overall union rate in our study is comparable with the other major studies done on pilon fracture.

Primary ORIF in fresh displaced pilon fracture gave satisfactory functional results. The anatomical or radiological outcomes did not always correlate with the functional outcomes. The functional outcome was seen to be even better in some of the patients who had less than adequate anatomical or radiological appearance.

Displaced fibular fractures should always be picked up for fibular plating in an attempt to contribute towards greater stability of the ankle mortice.

Limitations: A multi-centric randomized control trial, possibly triple blinded or at least double blinded in nature, involving a large number of patients with long term follow-up is needed to for making the study more significant.

Conflict of Interest : None

Source of Funding : None

Ethical Clearance: Taken

Declarations: (1) The Article is original with the author(s) and does not infringe any copyright or violate any other right of any third parties; (2) The Article has not been published (whole or in part) elsewhere, and is not being considered for publication elsewhere in any form, except as provided herein; (3) All author(s) have contributed sufficiently in the Article to take public responsibility for it and (4) All author(s) have reviewed the final version of the above manuscript and approve it for publication.

REFERENCES

1. Topliss CJ, Jackson M, Atkins RM: Anatomy of pilon fracture of distal tibia, *J Bone Surg Br*; 87:692-697,2005
2. Heim U, Naser M. Operative treatment of distal tibial fractures. Technique of osteosynthesis and results in 128 patients. *Arch Orthop Unfallchir* 1976;86(3):341-35
3. Roshdy M, El-Sallab, Bassiouni YE, Hany, El-Mwafi, Hammad AA. Staged Management of Comminuted Intra-articular Pilon Fracture. *Pan Arab J. Orth. Trauma*, January 2003;83-94.
4. Singh G, Cheema, Arora A, Sabat D, Singla J, Goel N, Maini L. The results of two-staged operative management of pilon fractures—a review of 25 cases. *JCOT* 2011;2(2)104-108.
5. Shabbir G, Hussain S, Nasir ZA, Shafi K, Khan JA. Minimal Invasive Plate Osteosynthesis Of Close Fractures Of Distal Tibia. *J Ayub Med Coll Abbottabad* 2011;23(2).121-124.
6. Tang X, Tang PF, Wang MY, Cheng LD, Zhen LM. Pilon fractures: a new classification and therapeutic strategies. *Chinese Medical Journal*; 2012;125(14):2487-2492.
7. Borens O, Kloen P, Richmond J, Roederer G, Levine DS, Helfet DL. Minimally invasive treatment of pilon fracture with a low profile plate: preliminary results in 17 cases. *Arch Orthop Trauma Surg.*; 2009 May;129(5):649-659.
8. Borg, Larsson LU. Percutaneous plating of distal tibial fractures: Preliminary results in 21 patients. *Injury* 2004;35,608-614.
9. Bourn RB, Roraback CH, Macnab J. Intra articular fractures of distal tibia: Pilon fracture. *J Trauma* 1983;23(7):591-596
10. Ruedi T, Matter P, Allgower M. Intra articular fractures distal tibial end. *Helv Chir Acta* 1968;3(5):556-582
11. Chen DY, Bing L, Ashwin A, Yun-feng Y, Zhou J, Guang Y. . Open reduction and internal fixation of posterior pilon fractures with buttress plate. *Acta Orthop Bras.* 2014; 22(1):48-53
12. Zeng XT, Pang GG, Ma BT, Mei XL, Sun X, Wang J, et al. Surgical treatment of open pilon fractures. *Orthop Surg.*; 2011 Feb;3(1):45-51.
13. Teeny SM, Wiss DA; Open reduction and internal fixation of tibial plafond fractures. Variables contributing to poor results and complication, *Clin Orthop Relate Res* 1993;292:108-117,.
14. Hasenboehler E, Rikli D, Babst R. Locking compression plate with minimally invasive plate osteosynthesis in diaphyseal and distal tibial fracture: a retrospective study of 32 patients. *Injury* 2007;365-370.
15. James Connor DPM, Michael CDPM, Lauren K DPM, Frank LDPM3, and Mark H DPM: pilon fracture: A review and update. *Northern Foot and Ankle journal* 2015;1(4):1-6.